

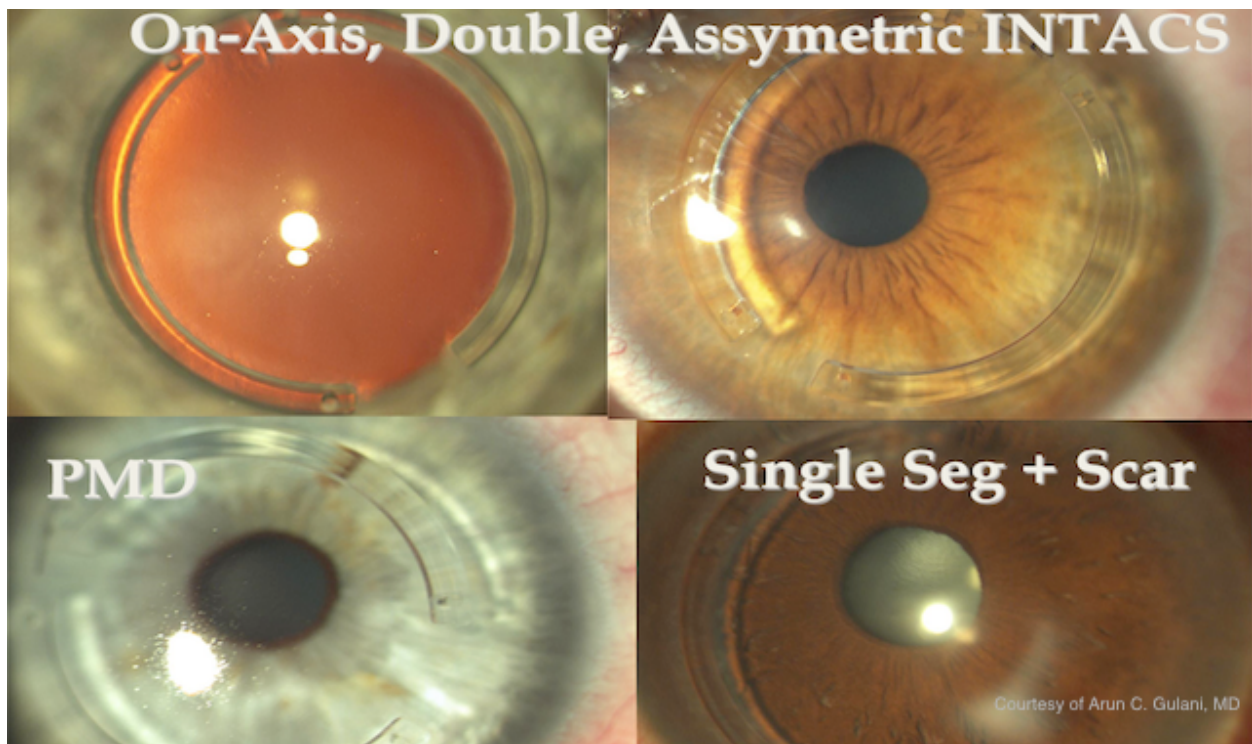
# Ophthalmology Times

CUTTING-EDGE ADVANCEMENTS

## Keratoconus as Refractive Surgery: Thinking Outside the 'Cone'

Adapting a planned approach for taming Keratoconus presentations to 20/20

By Arun C. Gulani, M.D., M.S.



The first issue to address is why is there a need for such a paradigm shift in thinking for keratoconus?

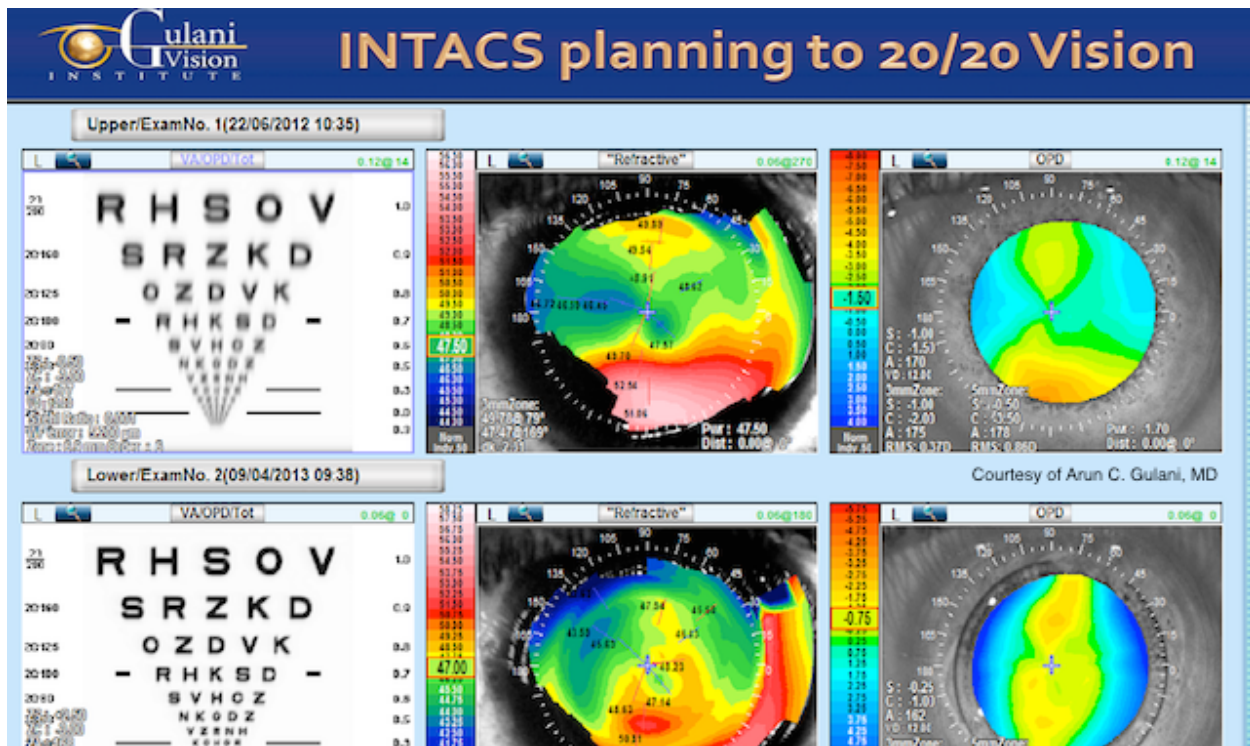
Over the past two decades of seeing patients with keratoconus from all over the world, I found many instances in which the referring surgeons have done an excellent job in helping their

patients, but the patients were still referred to me since they were dissatisfied with the vision endpoint.

In nearly every case, I found that had the surgeon only believed (mindset) that the patients could see 20/20, they could have completed their endeavor rather than reached a mediocre visual endpoint. Most of these surgeons were true heroes but could not collect their trophies due to their presumed notions resulting in limited endeavors.

Additionally, in many such cases, I did not have to undo the surgeon's work but instead I picked up the baton and took these patients to their vision end zone.

These referring surgeons also send me pages and pages of topographies and abstract vision tests that had compelled them to believe that each case of keratoconus was basically destined for poor vision and I found that my explaining to them to take the next step was always met with fear of success!



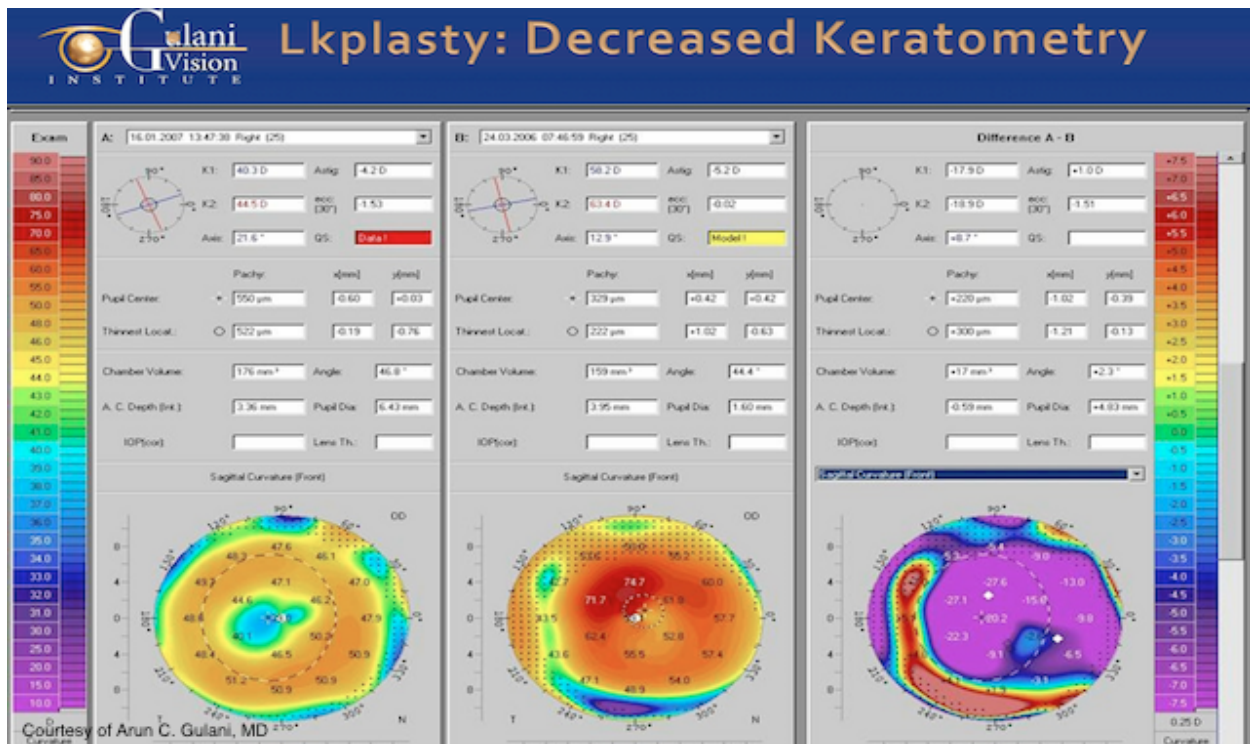
In this two-part column, I am sharing my experience of my own surprise at how well many patients with keratoconus can see and how that raised my own endeavor to always aim for unaided emmetropia in all patients unless their situation for any reason was a limitation to that end.

In this column, I encourage you to change your mindset. In the second part, I will share with you strategies and cases of patients with keratoconus with practically every presentation and combination I have seen over more than 2 decades and review how I planned my approach to their emmetropic outcomes.

First, let's recap a few basics. All ocular surgeries should end with the best vision that individual patients can achieve. This concept of using brief, topical, aesthetically pleasing, least interventional, and visually promising techniques singly or in combination is what I have introduced as a super-specialty called Corneoplastique.

Corneoplastique involves the full spectrum of kerato-lenticulo-refractive surgery to include all levels of LASIK, cataract, and corneal surgery to manipulate the optical elements of the eye singly or in a staged fashion and results in a final emmetropic outcome. The backbone of this thought process and surgical planning is based on the 5S system (I liken this system to a mental sorter).

Success in ophthalmology does not mean merely stopping progression of the patient's disease or execution of surgical acrobatics: If the eye has the potential for vision, then it is the surgeon's job to retain that vision or even to achieve better vision regardless of how complex the starting point. As long as there is no ongoing disease or irreversible blindness, every eye deserves unaided emmetropia.

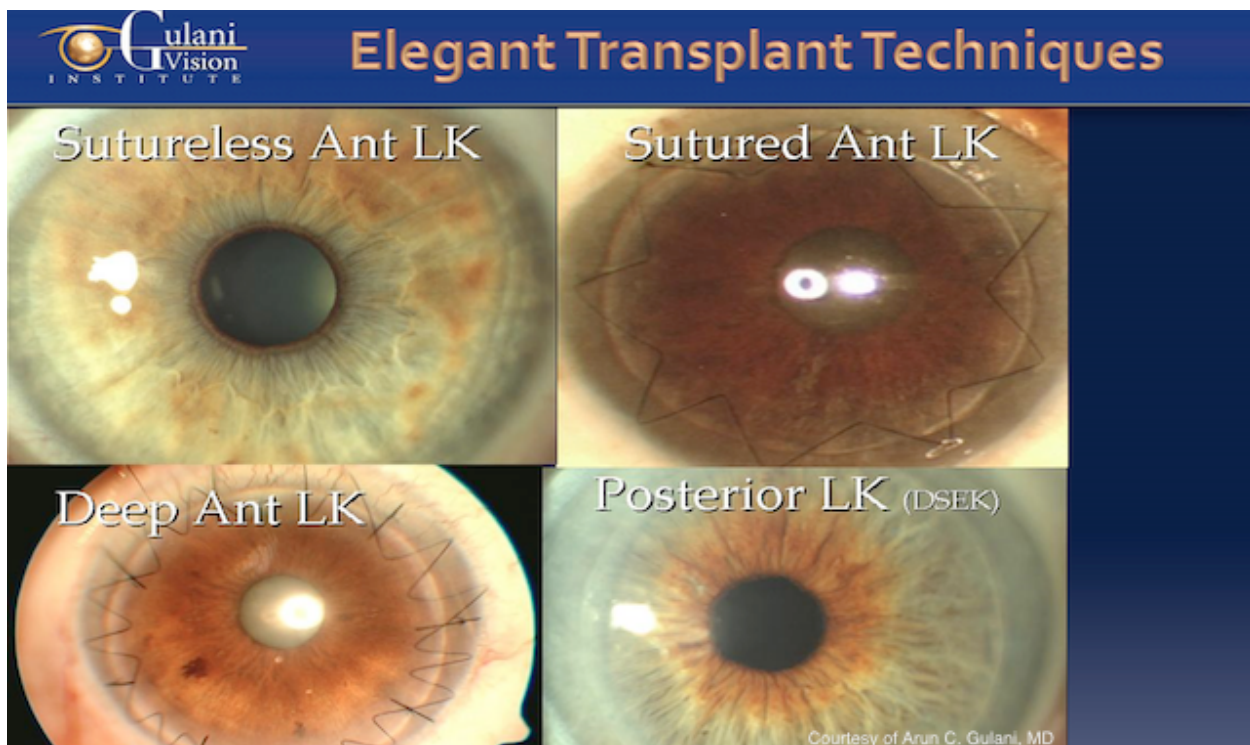


## CHANGING OUR MINDSET

Keratoconus is a word that creates immediate gloom for the patient and a lowered visual set-point for the diagnosing surgeon. It is a diagnosis that when heard by the patient, makes them immediately anxious to get onto Google, find out everything about the diagnosis, and then quickly come to a conclusion of two choices: an interventional transplant surgery or uncomfortable contact lenses, which either way provides less-than-perfect visual endpoints.

The surgeon in the meanwhile starts to think of all the latest and greatest advances in corneal transplant surgery that they could now use for yet another case and completely misses the point that in many cases of keratoconus, the patient could actually see and see even without glasses or contact lenses-with their own keratoconic cornea!

To avoid this knee-jerk reaction, I teach my fellows and visiting surgeons to break down the giant into a smaller, surmountable dwarfs and then confidently create a plan of attack, straight to emmetropia. In breaking down this giant, I help them visualize most keratoconus cases as nothing more than a thin cornea with high keratometry, decentered apex, irregular astigmatism, and associated ametropia (myopia or hyperopia). By breaking down the disease into its smaller components, it becomes conquerable. Now take this mindset further and actually imagine that these patients should deserve refractive surgery candidate expectations.



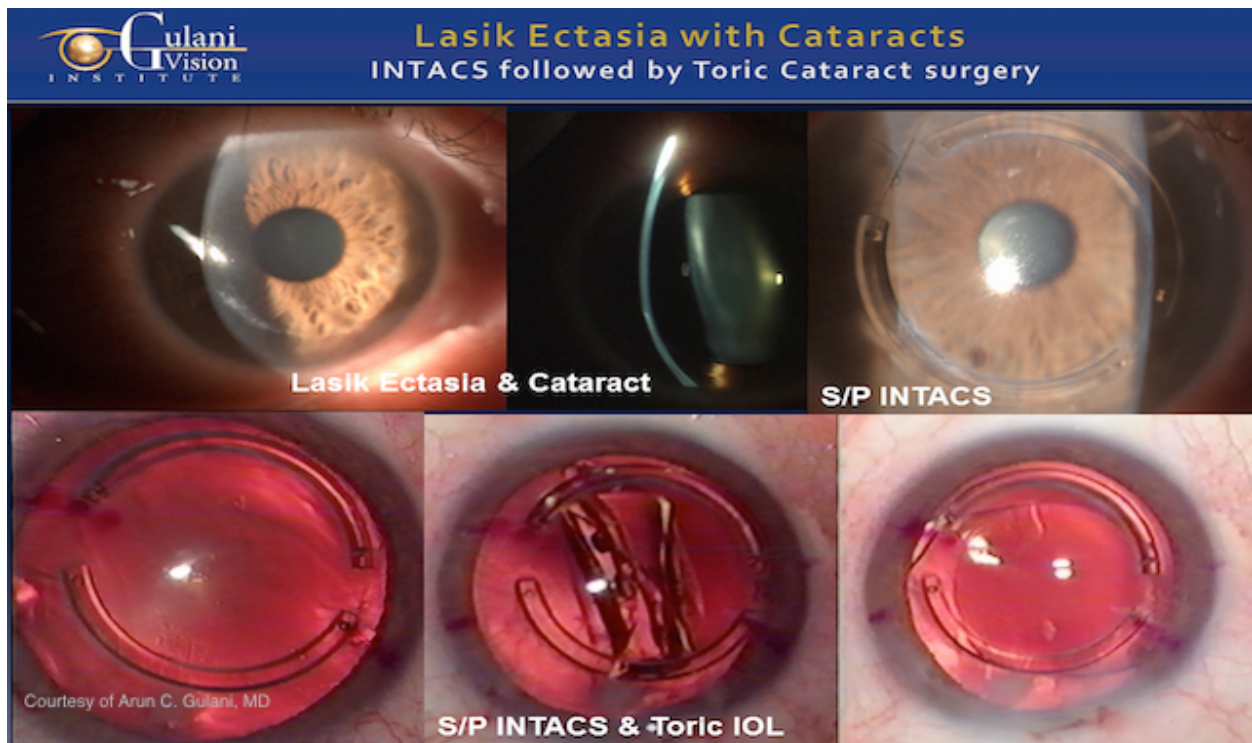
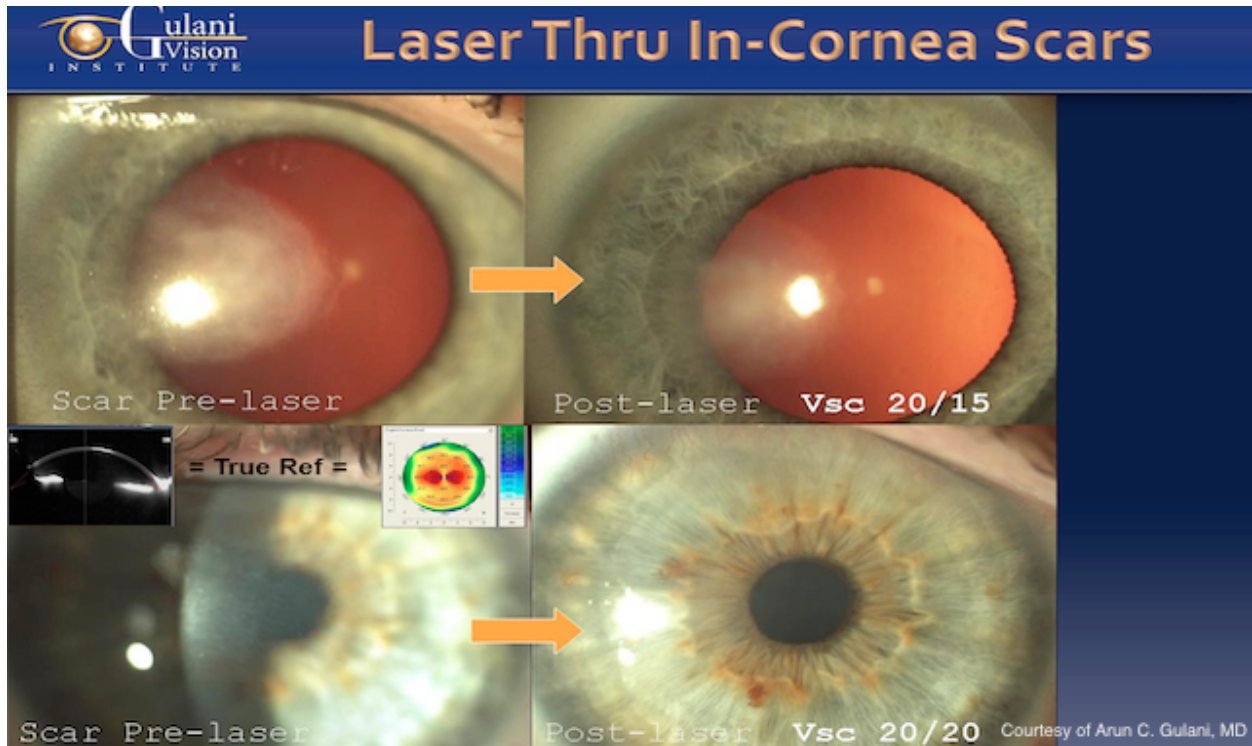
As I proposed previously, size down any complications by sorting through the 5S system to break them down into simple components of visual impact and see your plan of action unfurl before your eyes so this so-called complex condition will logically and elegantly sort itself out into simplistic components that adversely affect vision and present themselves to be corrected in a single or staged fashion.

Consider, for example, the case of a patient with keratoconus with a corneal thickness of  $450 \mu\text{m}$  and a documented cone on topography with low myopia (1 diopter or less) and high astigmatism (up to 5 D). In terms of the 5S system, we first want to make sure that he has potential to see, i.e., sight (visual acuity [VA]). Although the patient cannot tolerate hard contacts, the optometrist has noted that he has a VA of 20/25 with them.

Therefore, whatever we do, the patient should still have a VA of 20/25 or better. The patient has sight, there is no scar, and the site (center or periphery) is unaffected. Moreover, we know the

patient has a relatively thin cornea (strength) and high astigmatism (shape). In terms of the 5S system, we must therefore correct for sight and shape.

Now using our Gulani-Nordan criteria for laser PRK candidacy, I would review that approach in this case and also categorize with patient using the following classification.



## GULANI CLASSIFICATION SYSTEM FOR LASER SURGERY IN KERATOCONUS

I. Laser as primary treatment (In this subset, the patient is informed that we can strive for vision directly with the laser keeping the surgical interventions noted in level II as a backup plan to be applied in single or combined approaches to address any complication induced or progression of cone if needed).

Class I: Clear cornea

Class II: Scarred cornea

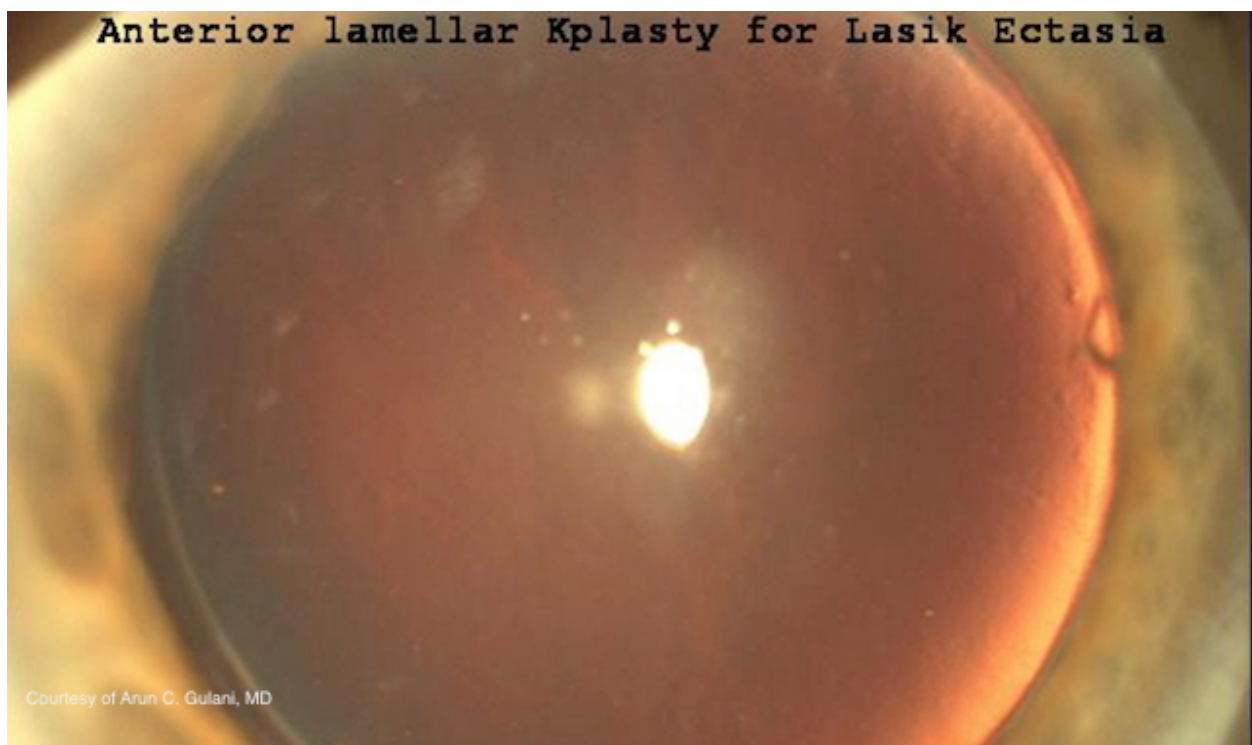
II. Laser as staged secondary treatment

Class I after corneal surgery:

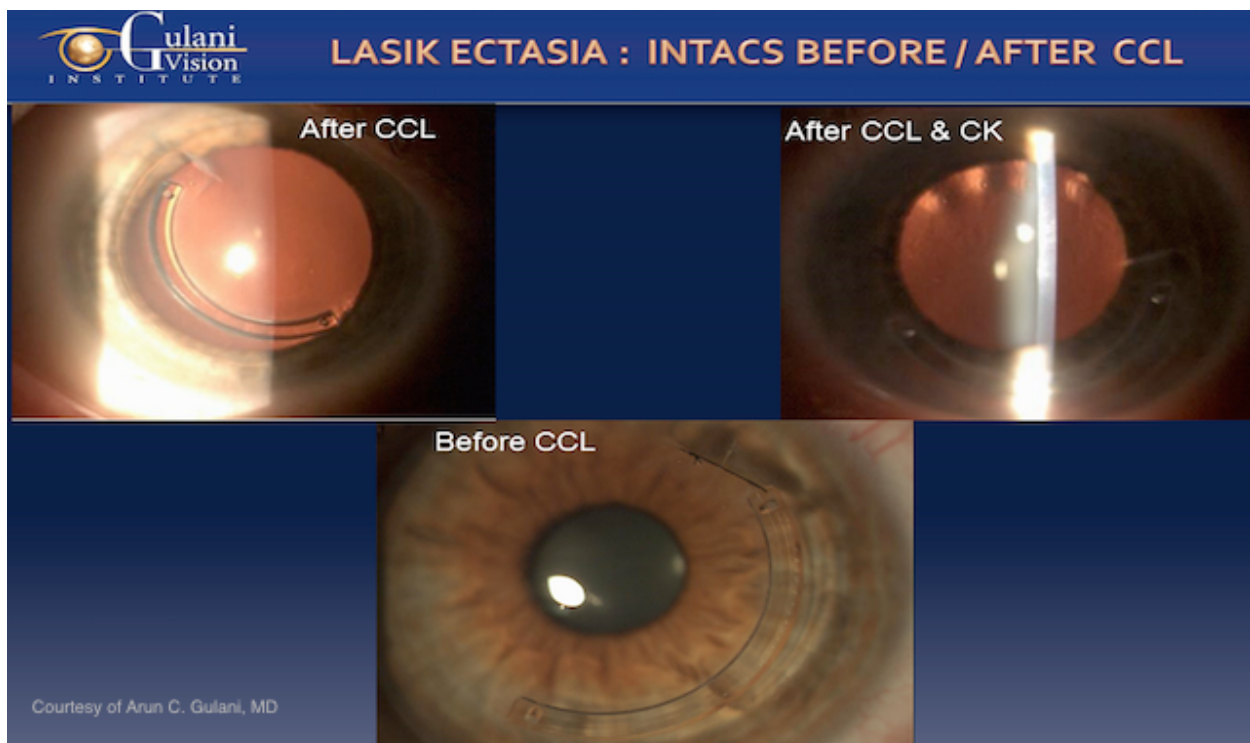
- a. Intacs (Addition Technology, Inc.)
- b. Lamellar keratoplasty (femtosecond laser, manual)
- c. Penetrating keratoplasty
- d. Collagen crosslinking
- e. Conductive keratoplasty

Class II after intraocular surgery

- a. Phakic implant (anterior, posterior)
- b. Cataract surgery with lens implant (monofocal, toric, accommodative, piggyback)



In this case, the corneal strength is adequate and there is no scar, and therefore no need for lamellar keratoplasty. Continuing with this example, I would perform laser advanced surface ablation (ASA) surgery, because astigmatic treatments remove the least tissue and correct the astigmatism to bring the VA close to 20/20. From a medicolegal standpoint, I would explain to the patient that, with this technique, I should be able to reshape the cornea to provide predictable vision. I would remind them that the outcome would not be like that of a virgin eye with 20/20 VA. I would also inform the patient that I have Intacs as a backup option if their keratoconus progresses naturally or because of the laser.



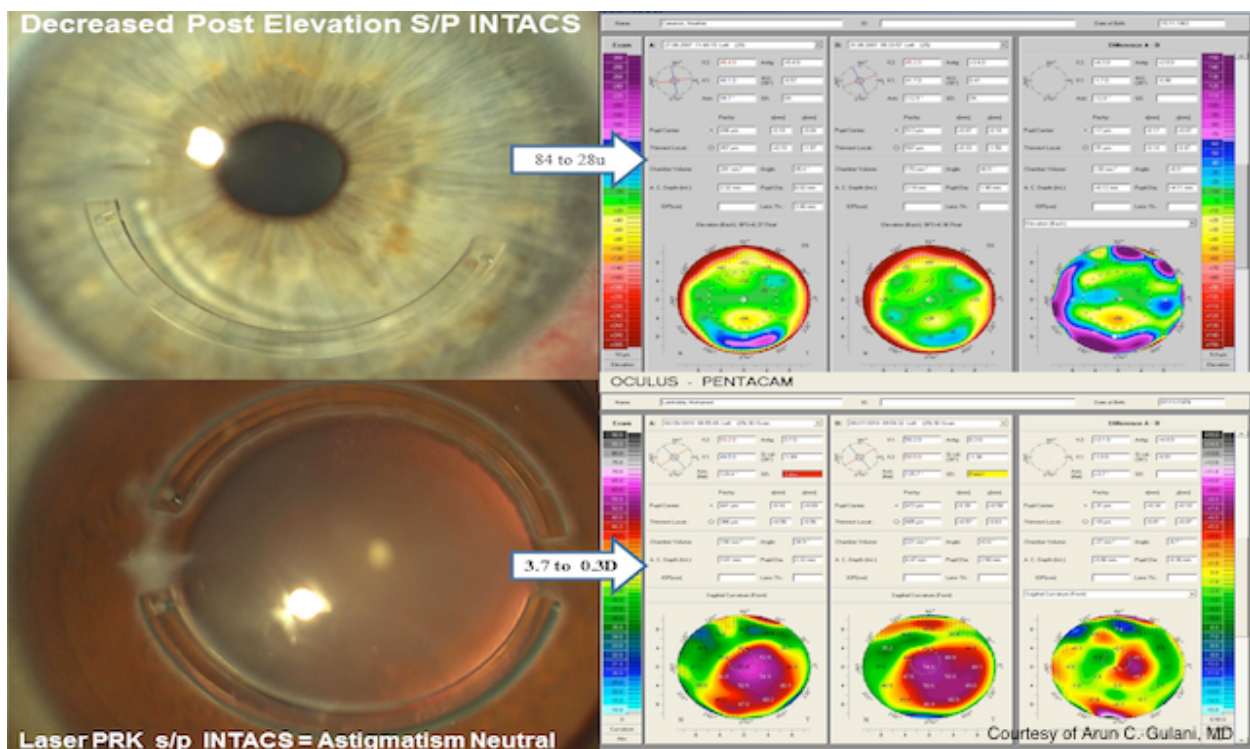
I also explain the use of corneal collagen crosslinking (CXL) as a staged part of any of these surgeries, because it can stabilize this new shape (following laser vision surgery). I teach surgeons that they should first correct the sciotic spine (corneal shape = vision) before making the shape permanent with CXL unless the cornea is changing enough to justify CXL before any refractive correction.

Now let's look at the same case and consider that it has a thinner cornea with a best-corrected VA less than 20/40. Now I would choose Intacs surgery.

The most common Intrastromal Corneal Ring Segments (ICRS) are Intacs, which are semicircular inserts made of polymethylmethacrylate.

I tell patients that having this kind of keratoconus is like being 11 feet tall. People of normal height go to the mall and buy a suit based on their measurements. I say, I am going to put you in braces (Intacs) and make you 6'5" or 5'8". I don't know for sure because Intacs are not mathematically predictable, but I know that you will be moving in the right direction, and the chances are that you will be able to walk into a mall and find a suit that will fit, i.e., Intacs help get patients back into contact lenses and glasses. I perform Intacs in various forms, single, paired, steep axis, and varied various thicknesses and sizes to customize each shape effectively.

I can also perform Laser ASA over the Intacs to treat residual astigmatism. Again, astigmatic laser procedures remove the least tissue, and I have achieved stability and safety with the braces (Intacs) in place. Crosslinking also provides a stability factor which can be timed accordingly.



Now let's add a scar to this same patient and using our 5S system we now need to clear the scar while correcting the shape Keeping our in-cornea and on-cornea scar approach, we shall proceed with Laser PRK and use the above-mentioned protocol.

Now let's keep scar and also make the cornea thinner and more unstable.

Based on the 5S system, I now need to not only clear the central scar but also add (Strength, i.e., thickness)



**Gulani Vision INSTITUTE**

**ALK Ectasia with Unstable Cornea & Cataract**  
**Assymetric INTACS to prepare for Cataract Surgery**

**Astigmatism**  
**10.1 to 2.7D**

Courtesy of Arun C. Gulani, MD

**Gulani Vision INSTITUTE**

**Thin Keratoconus with Scar with Cataract**  
**Lamellar Kplasty followed by Cat surgery with Toric IOL**

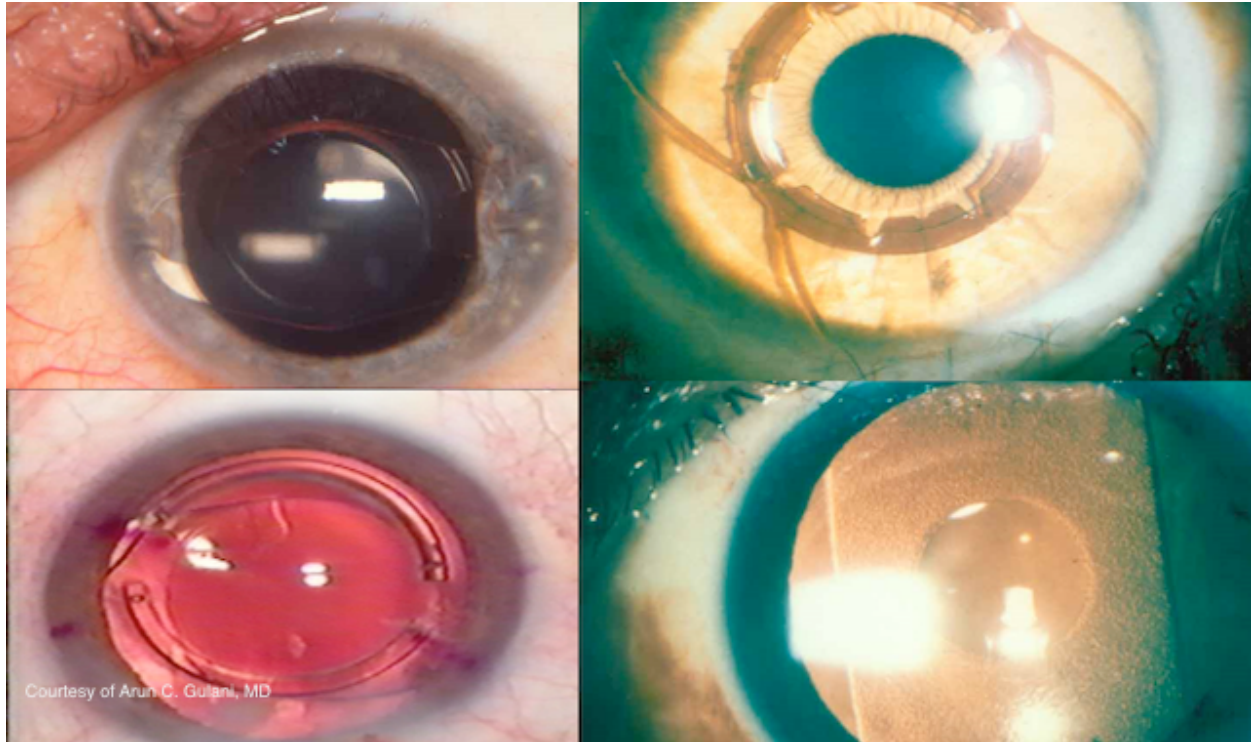
**Thinned Keratoconus with Scar**

Courtesy of Arun C. Gulani, MD

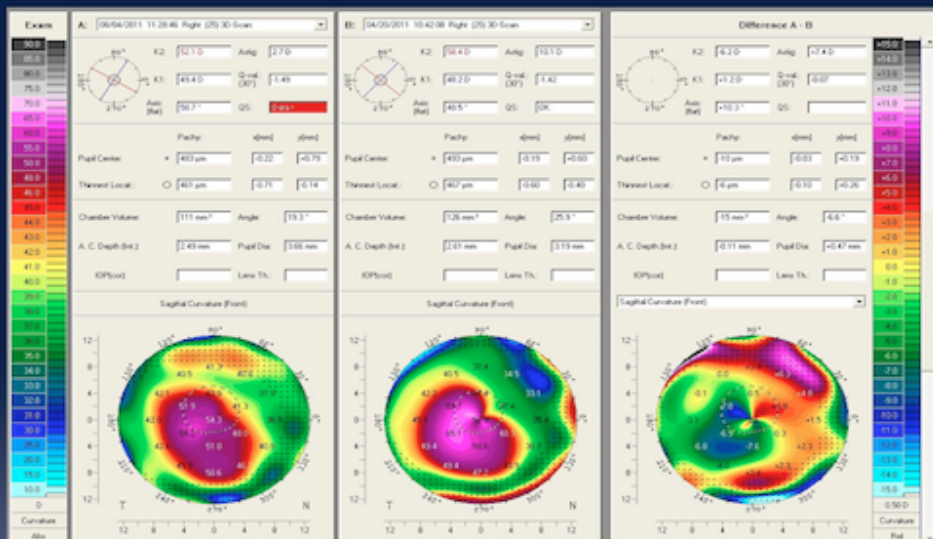
Such a patient therefore can undergo a variety of lamellar corneal transplants to address these affected systems. Six months to 1 year later, we can perform laser ASA for the

refractive error (correcting Shape) aiming for an emmetropic outcome.

In many cases, high myopia could be the main culprit along with astigmatism and here, depending on the age of the patient, he or she can undergo a phakic implant surgery such as Implantable Contact Lens (ICLs) or if in the cataract age group, cataract surgery with monofocal or toric intraocular lenses (IOLs).



**Gulani Vision INSTITUTE** **INTACS for ALK Ectasia bringing Astigm down from 10.1 to 2.7D prior to Cataract Surgery**



Courtesy of Arun C. Gulani, MD

## CXL AND REFRACTIVE KERATOCONUS SURGERY

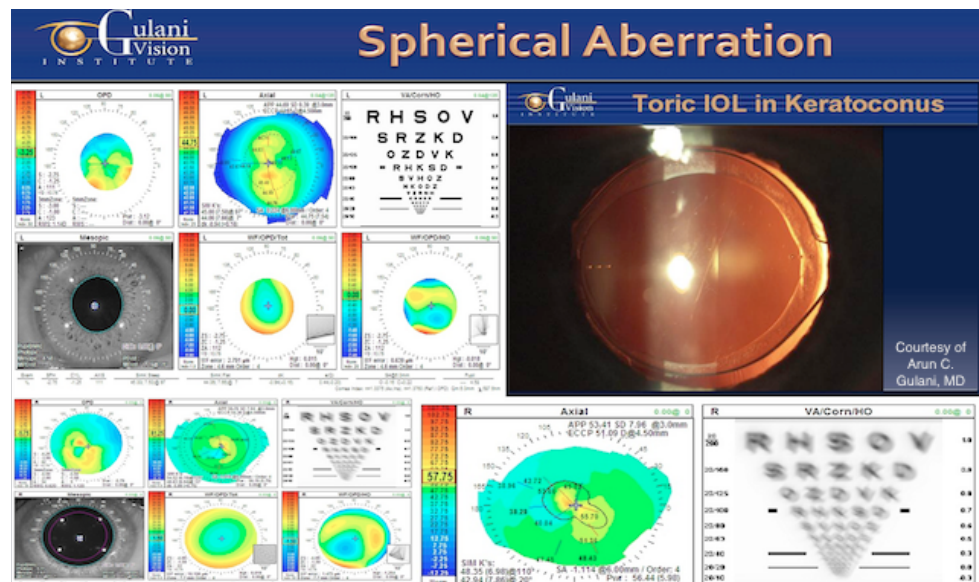
The recent FDA approval of CXL is a boon to patients with keratoconus. I believe that crosslinking could become the final step in every keratorefractive surgery to stabilize and make their outcomes permanent.

CXL also can be performed before refractive surgery in cases of fluctuating refractions/topographies, and once the cornea has become stable and measureable, refractive approaches can be planned.

CXL consists of application of riboflavin (vitamin B2) to saturate the corneal stroma followed by activation with ultraviolet (UV) light. The resulting photochemical reaction causes collagen to form additional covalent connections between fibers, strengthening the collagen structure within the corneal stroma.

An exciting new development in the pipelines is a system by Avedro, which can deliver UV light to the cornea in different patterns and shapes. This system can be used to perform photorefractive intrastromal crosslinking (PiXL). PiXL has the potential to change corneal curvature to achieve a refractive effect. This has advantages over excimer laser treatment because it works without removing tissue and could be that modality I have been manually combining for over a decade.

In conclusion, using the 5S system, we can approach practically any ocular situation from virgin refractive errors to keratoconus. Once we develop the mindset of looking at keratoconus with a new level of commitment and expectations, we can start designing vision with the same responsibility and passion as we do in refractive surgery cases.

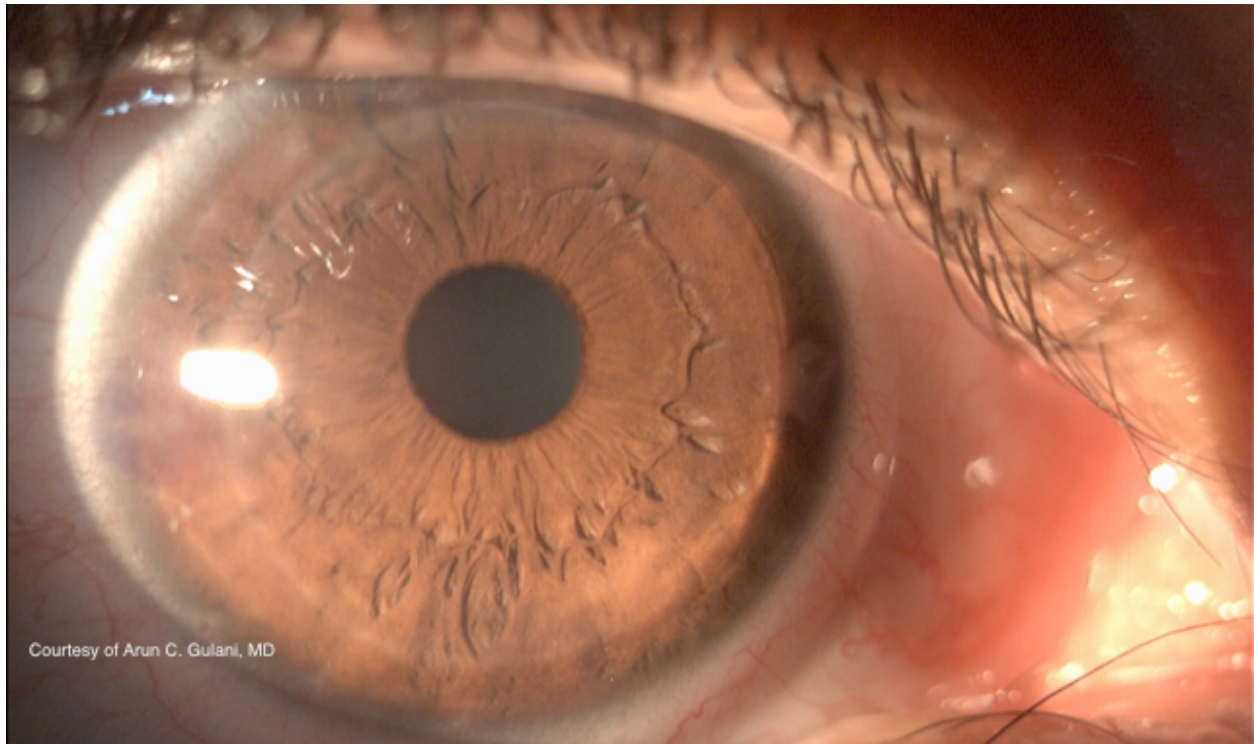


By first working with the patient's optometrist, I can get a picture of the patient's refractive stability and history and his or her visual potential from a hard contact lens trial. It is then my job to maintain that level of vision or improve it.

Of course, there will be cases with extreme levels of keratoconus that require a corneal transplant. However, even when performing a transplant, surgeons should not forget to take the patients to their next level of vision in a staged fashion.

June 15th, 2016

Approaching keratoconus as a refractive surgery will change the way both ophthalmologists and patients will approach this surmountable condition to bring in a new era of not only relieving but also enhancing the lifestyle of this deserving patient population.



Thinking outside the 'cone' with kerato... ⌚ ↗

**C3-R Mechanism**  
UVA  
Riboflavin

Arun C. Gulani, M.D.